

Osseointegration and soft tissue response to gradually anodized surface implants: Real-world data from a 1000-patient study including clinically compromised subpopulations.

Daniele de Santis¹, Miguel Roig Cayón², Giacomo Fabbri³, Tristan Staas⁴, Ville Männistö⁵, Tricia Crosby⁶, Hadi Antoun⁷, Wolfgang Prinz⁸, Ana Ferro⁹, Miguel de Araújo Nobre⁹, Roberto Sleiter¹⁰, Flavio Brunner¹¹, Stefan Scherg¹², Thomas Eshraghi¹³, Jan Kowar¹⁴, Eduard Crooke¹⁵, Renaud Noharet¹⁶, Simon Kold¹⁷, Louise Kold¹⁷, Robert Haas¹⁸, Massimiliano Guazzato¹⁹, Matthieu Ghibaudo²⁰, Pieter Avontroodt²¹, Gerry Raghoobar²², Juan Mesquida²³, Robert Stillmann²⁴, Graham Carmichael²⁵, Glen Liddelow²⁵

¹Azienda Ospedaliera Universitaria Integrata, Verona, Italy, ²Clinica Lluç, Barcelona, Spain, ³Studio Odontoiatrico Specialistico, Cattolica, Italy, ⁴Staas & Bergmans Zorgvoorzorgmond B.V., Hertenbosch, Netherlands, ⁵Dental Center Helmiäinen, Tampere, Finland, ⁶Midwest Dental Implantology, Saint Charles, IL, United States, ⁷IFCIA, Paris, France, ⁸Bodensee-Implantat-Zentrum AG, Rorschach, Switzerland, ⁹Malo Clinic, Lisbon, Portugal, ¹⁰Dentalspecialist, Egerkingen, ¹¹Brunner Praxis für Zahnmedizin, Luzern, Switzerland, ¹²DrS - Schöne Zähne, Karlstadt, Germany, ¹³Periodontal Associates, Tualatin/Beaverton/Portland, OR, United States, ¹⁴Folkandvården Västra Götalan, Bränemarkkliniken, Göteborg, Sweden, ¹⁵Clinica Dental Crooke & Laguna, Malaga, Spain, ¹⁶Cabinet du Dr Noharet, Lyon, France, ¹⁷Herning Implant Center, Herning, Denmark, ¹⁸Klinik für Orale Implantologie GmbH & Co KG, Vienna, Austria, ¹⁹Pyrmont Dental Specialist/Specialised Dental, Pyrmont/Bowral, NSW, Australia, ²⁰BGLP, Montpellier, France, ²¹ParoBreda- Parodontologie & Implantologie, Breda, ²²Dept Oral and Maxillofacial Surgery, University Medical Center, Groningen, Netherlands, ²³Altés & Mesquida, Palma de Mallorca, Spain, ²⁴Implantologie und Ästhetische Zahnheilkunde, Vienna, Austria, ²⁵Bränemark Center, Perth WA, Australia

CLINICAL RELEVANCE

- A gradually anodized implant surface designed to minimize bacterial adhesion and reduce the risk of peri-implantitis showed healthy soft tissue response and robust osseointegration.
- Early favorable clinical outcomes in a real-world patient population, including individuals with comorbidities and those requiring bone grafting, suggests broad applicability of this hybrid surface.

BACKGROUND AND AIM

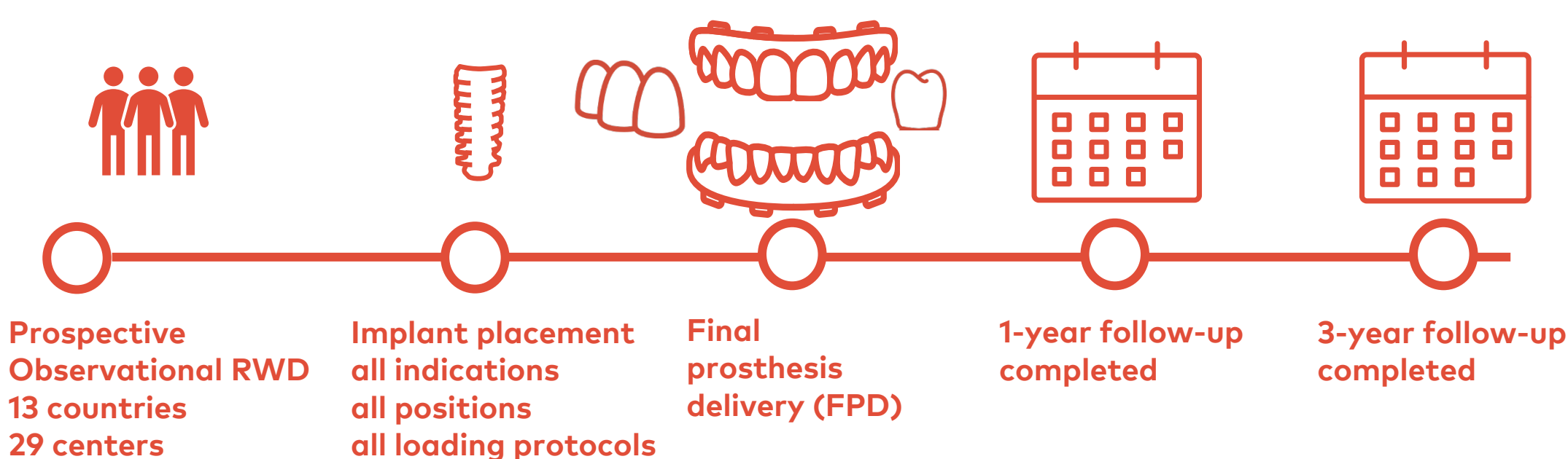
Enhancing osseointegration and promoting healthy soft tissue outcomes strive to expand the successful use of implant-based oral rehabilitations for patients with comorbidities and other challenging conditions. Optimizing the implant surface by gradual anodization from a moderately rough apex to the minimally rough collar¹ employing various implant geometries endeavors to achieve this goal.

This study aimed to evaluate the clinical performance of TiUltra surface implants in a prospective real-world data (RWD) collection from routine clinical practice and a diverse population of consecutive patients not subject to the strict eligibility criteria nor a specified protocol typically enforced in a clinical trial

METHODS AND MATERIALS



Figure 1. The four implant systems used in the study.



Group	Patients	Implants
N1	256	334
NA	261	353
NRC	262	450
NPC	247	427

Figure 2. Study flow-chart. Data according to extraction on 9 July 2025.

RESULTS

- Mean patient age was 53.2 ± 11.71 years (range 18-71) with females comprising 54.9% of the population.
- Of the 1026 patients, 81 (7.9%) were nicotine users, 45 (4.4%) had parafunctional tendencies, 86 (8.4%) had a history of periodontitis, 16 (1.6%) of peri-implantitis, 18 (1.8%) of severe oral mucositis, 23 (2.2%) diabetes, and 61 (5.9%) other significant diseases including osteoporosis, took bisphosphonates, or had various cancers (but no oral cancer).
- Simultaneous GBR was administered at 25.3% of implant sites.
- Of the 1564 implants placed in 1002 treated patients, 35 failures occurred during the 0-42.8 months of follow-up.




Figure 3. Implant survival. The graphs illustrate implant failures recorded from 0 to 42.8 months of follow-up (*as of data extraction on 9 July 2025) in the total population, and 2 subpopulations. Comorbidities include medical conditions plus smoking. Note only a slight increase in failure rates in the given subpopulations compared to the general population.

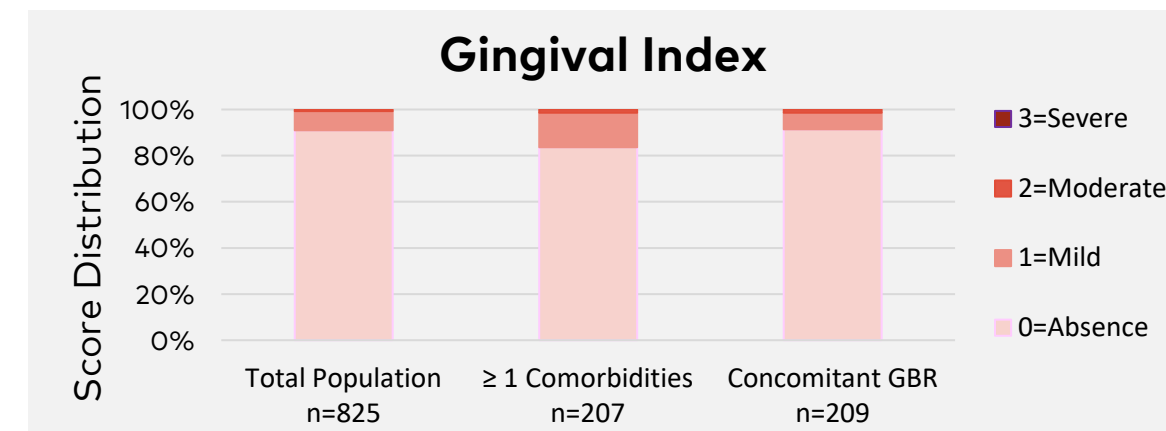


Figure 4. Inflammation score evaluated as a soft tissue health indicator at the restored implant sites at the 1-year post-FPD. Note the absence of severe inflammation at any implant site and the comparable soft tissue health score distribution between the general and the more challenging subpopulations.

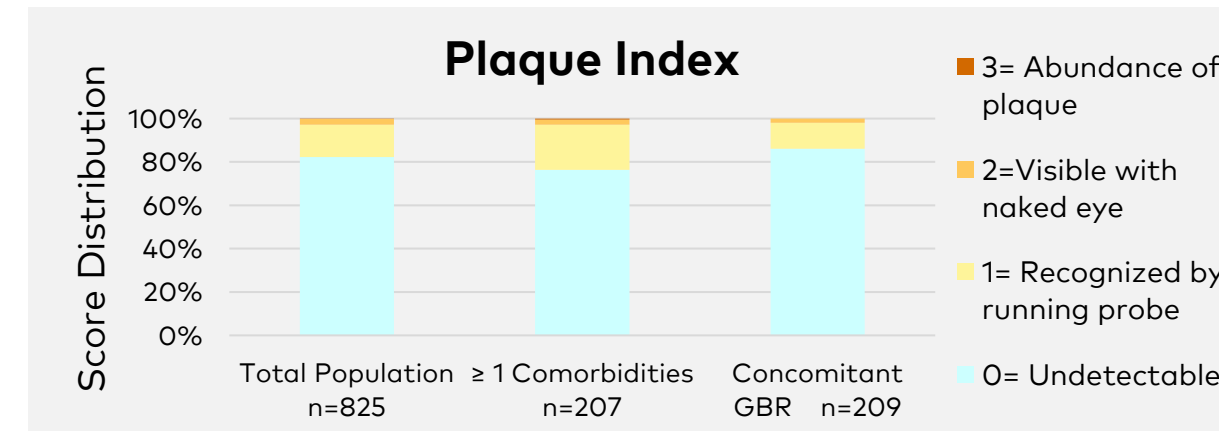


Figure 5. Plaque accumulation assessed at the 1-year post-FPD. Note predominantly undetectable or low levels of plaque at implant sites and the comparable score distribution between the general and the more challenging subpopulations.

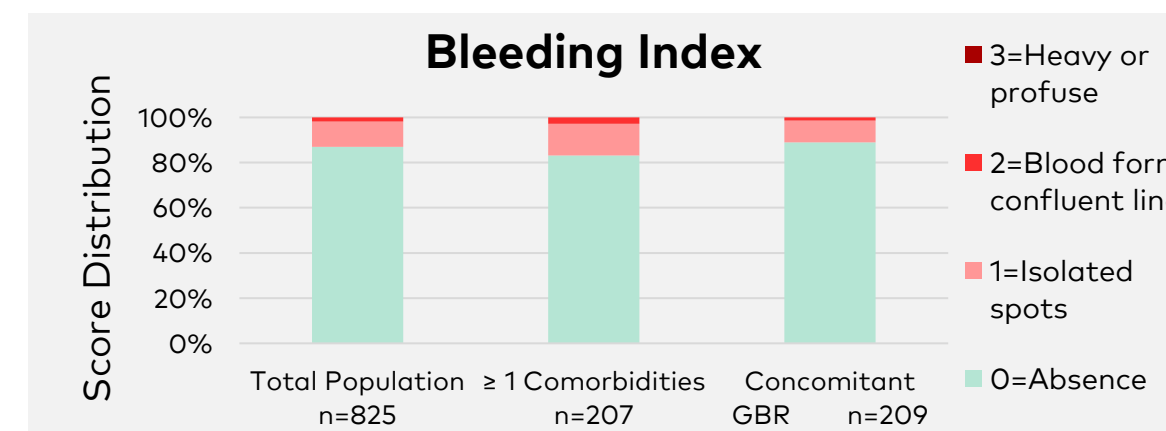


Figure 6. Bleeding scores assessed as soft tissue health indicators at restored implant sites at the 1-year post-FPD follow-up. Note the absence of heavy or profuse bleeding for any implant site and the comparable soft tissue health status between the general and the more challenging subpopulations.

CLINICAL CASE(S)

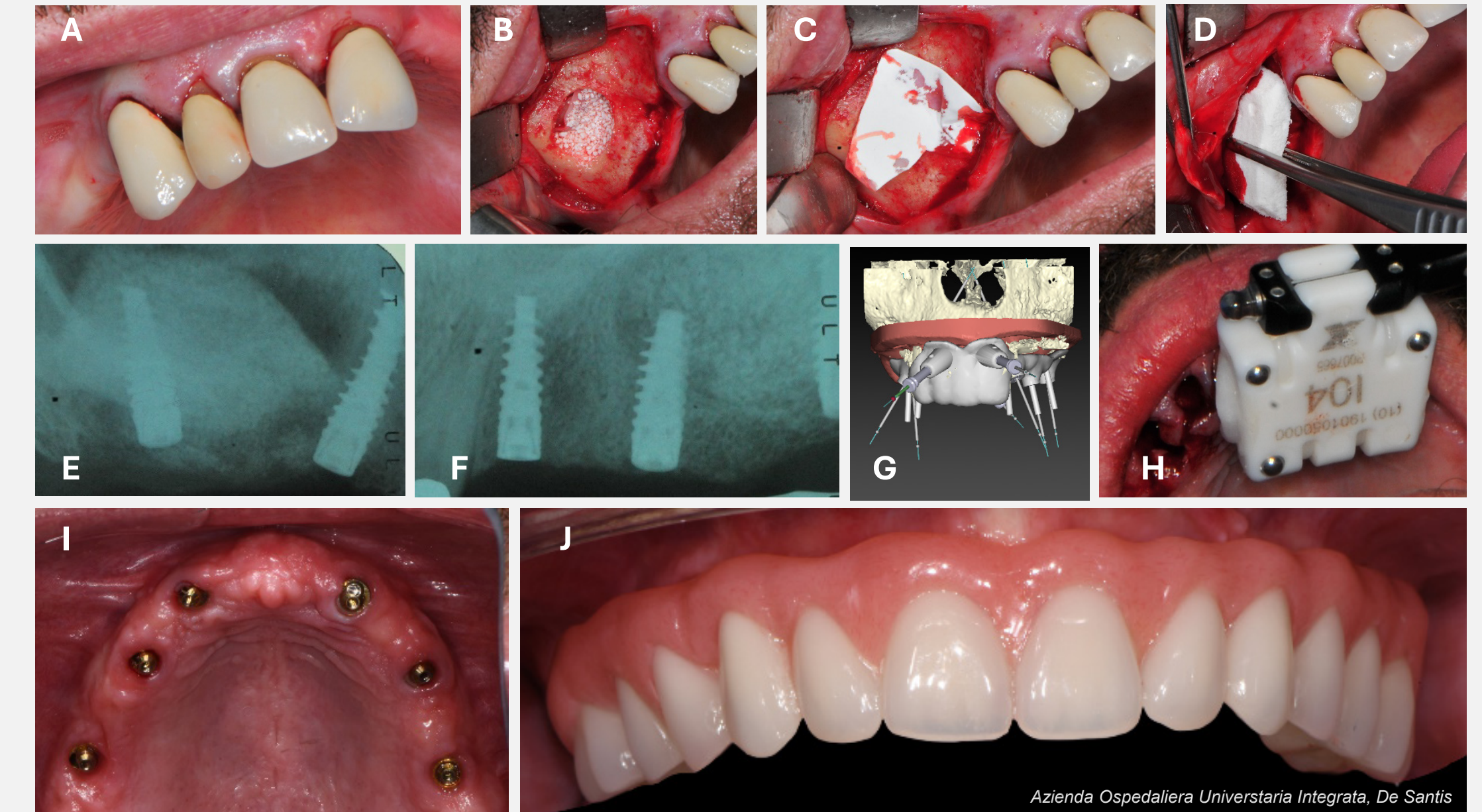


Figure 7. A clinical case from the study. A 53-year-old male smoker patient with alveolar ridge atrophy and hopeless dentition in the maxilla (A) underwent GBR (B,C) and soft tissue regeneration (D) and the site was sutured (E). Subsequently, five implants (NobelActive TiUltra; E,F) were placed using static guide. The remaining dentition served to plan the placement of the sixth implant, which took place the same day using dynamic navigation (G,H). Final prosthesis delivery (I,J) took place 20.4 months after implant placement.

CONCLUSION

Within the limitation of this interim analysis, the gradually anodized surface implants showed high survival, and minimal inflammation, bleeding, and plaque accumulation. These results suggest that the hybrid surface promotes successful early osseointegration and healthy peri-implant tissue response supporting its applicability in everyday practice. Comparable results between different subpopulations including patients with comorbidities and bone defects imply predictability of clinical outcomes even under challenging conditions.